



Since January 2020 Elsevier has created a COVID-19 resource centre with free information in English and Mandarin on the novel coronavirus COVID-19. The COVID-19 resource centre is hosted on Elsevier Connect, the company's public news and information website.

Elsevier hereby grants permission to make all its COVID-19-related research that is available on the COVID-19 resource centre - including this research content - immediately available in PubMed Central and other publicly funded repositories, such as the WHO COVID database with rights for unrestricted research re-use and analyses in any form or by any means with acknowledgement of the original source. These permissions are granted for free by Elsevier for as long as the COVID-19 resource centre remains active.

CASE REPORT

BEGINNER

CLINICAL CASE SERIES

Long-Haul Post-COVID-19 Symptoms Presenting as a Variant of Postural Orthostatic Tachycardia Syndrome

The Swedish Experience

Madeleine Johansson, MD, PhD,^{a,b,*} Marcus Ståhlberg, MD, PhD,^{c,d,*} Michael Runold, MD, PhD,^e Malin Nygren-Bonnier, PhD, PT,^{f,g} Jan Nilsson, MD, PhD,^a Brian Olshansky, MD,^h Judith Bruchfeld, MD, PhD,^{i,j,†} Artur Fedorowski, MD, PhD^{a,b,†}

ABSTRACT

Major clinical centers in Sweden have witnessed an inflow of patients with chronic symptoms following initial outpatient care for coronavirus disease-2019 (COVID-19) infection, suggestive of postural orthostatic tachycardia syndrome. This report presents the first case series of 3 Swedish patients diagnosed with postural orthostatic tachycardia syndrome more than 3 months after the primary COVID-2019 infections. (**Level of Difficulty: Beginner.**) (J Am Coll Cardiol Case Rep 2021;■:■-■) © 2021 The Authors. Published by Elsevier on behalf of the American College of Cardiology Foundation. This is an open access article under the CC BY-NC-ND license (<http://creativecommons.org/licenses/by-nc-nd/4.0/>).

Postural orthostatic tachycardia syndrome (POTS) is the most prevalent chronic cardiovascular dysautonomia among young and middle-age individuals, predominantly women. It is characterized by chronic orthostatic intolerance, abnormal heart rate (HR) increase on standing, and deconditioning (1,2) (Table 1). The syndrome has been postulated to have post-viral autoimmune activation as a possible etiology (3).

LEARNING OBJECTIVES

- To raise awareness of POTS as a possible long-term complication following COVID-19 infection.
- To present diagnostic principles for an accurate POTS diagnosis.
- To propose treatment regimens in patient with persistent POTS symptoms.

From the ^aDepartment of Clinical Sciences, Faculty of Medicine, Lund University, Malmö, Sweden; ^bDepartment of Cardiology, Skåne University Hospital, Malmö, Sweden; ^cHeart, Vascular, and Neuro Theme, Karolinska University Hospital, Stockholm, Sweden; ^dDepartment of Medicine Solna, Karolinska Institutet, Stockholm, Sweden; ^eDepartment of Respiratory and Allergic Diseases, Karolinska University Hospital, Stockholm, Sweden; ^fDepartment of Neurobiology, Care Sciences and Society, Division of Physiotherapy, Karolinska Institutet, Karolinska University Hospital, Stockholm, Sweden; ^gFunction Allied Health Professionals, Medical Unit Occupational Therapy and Physiotherapy, Karolinska University Hospital, Stockholm, Sweden; ^hDepartment of Internal Medicine, Division of Cardiology, University of Iowa Hospitals, Iowa City, Iowa; ⁱDepartment of Infectious Diseases, Karolinska University Hospital, Stockholm, Sweden; and the ^jDivision of Infectious Diseases, Department of Medicine Solna, Karolinska Institutet, Stockholm, Sweden. *Drs. Johansson and Ståhlberg contributed equally to this work and are joint first authors. [†]Drs. Bruchfeld and Fedorowski contributed equally to this work and are joint senior authors.

The authors attest they are in compliance with human studies committees and animal welfare regulations of the authors' institutions and Food and Drug Administration guidelines, including patient consent where appropriate. For more information, visit the [Author Center](#).

Manuscript received December 10, 2020; revised manuscript received January 11, 2021, accepted January 15, 2021.

**ABBREVIATIONS
AND ACRONYMS****BP** = blood pressure**COVID-19** = coronavirus
disease-2019**HR** = heart rate**POTS** = postural orthostatic
tachycardia syndrome**SARS-CoV-2** = severe acute
respiratory syndrome-
coronavirus-2

In the acute phase, coronavirus disease-2019 (COVID-19) causes multiple complications including pneumonia, respiratory distress syndrome, liver injury, cardiac injury, and prothrombotic coagulopathy. Long-term consequences remain unknown (4). Recently, chronic (“long-haul”) symptoms following COVID-19 infections have been consistent with a POTS-like presentation (4). Here we present a series of 3 patients with chronic post-COVID-19 symptoms diagnosed as POTS.

PATIENT #1

In March 2020, a 42-year-old woman with history of allergic rhinitis and conjunctivitis developed flu-like symptoms including malaise, cough, fever, weakness, loss of appetite, myalgia, and loss of smell and taste. She did not seek medical attention and her condition improved progressively but, in May, symptoms recurred with the addition of abdominal pain and odynophagia. Chest computed tomography and laboratory testing were normal. A nasopharyngeal swab showed no evidence of COVID-19.

In July, debilitating symptoms of profound exhaustion with associated sinus tachycardia

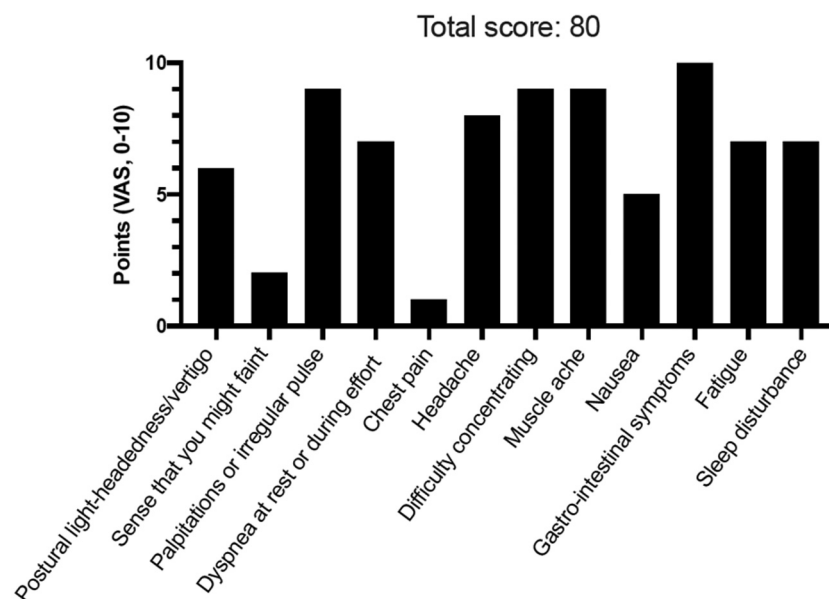
TABLE 1 Diagnostic Criteria of POTS

Diagnostic Criteria
Sustained heart rate increment of not less than 30 beats/min or above 120 beats/min within 10 min of active standing or head-up tilt. For individuals who are younger than 19 years the required increment is at least 40 beats/min.
Absence of orthostatic hypotension (i.e., sustained systolic blood pressure drop of not less than 20 mm Hg).
Reproduction of spontaneous symptoms such as light-headedness, palpitations, tremulousness, generalized weakness, blurred vision, and fatigue. In some patients, tachycardia may evoke vasovagal syncope corresponding to spontaneous attacks from patient's history.
History of chronic orthostatic intolerance and other typical POTS-associated symptoms (for at least 6 months (1)).
Absence of other conditions provoking sinus tachycardia such as anxiety disorders, hyperventilation, anemia, fever, pain, infection, dehydration, hyperthyroidism, pheochromocytoma, use of cardioactive drugs (sympathomimetics, anticholinergics).

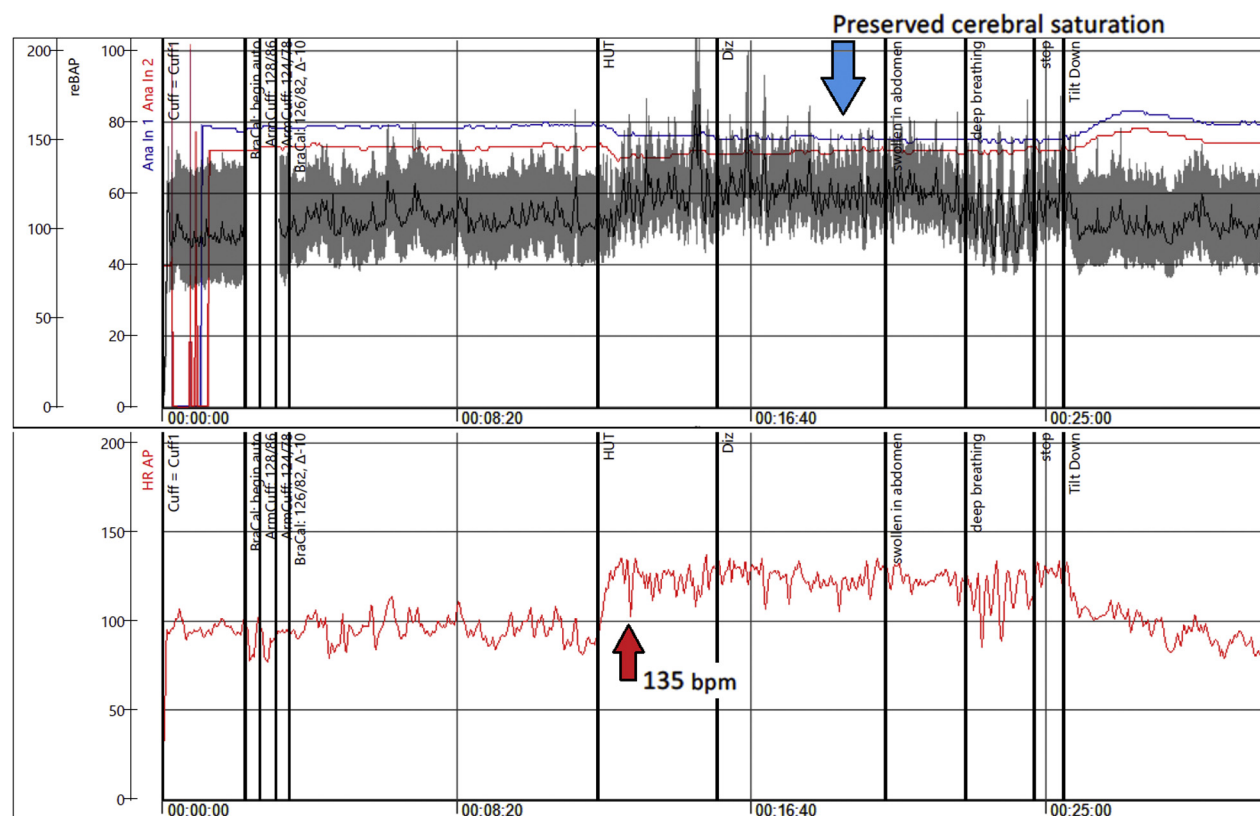
This table has been endorsed by the American Academy of Neurology, the American Autonomic Society, the American College of Cardiology, the American Heart Association, the European Federation of Autonomic Societies, the European Heart Rhythm Association, the European Society of Cardiology, and the Heart Rhythm Society. Adopted with permission from Fedorowski (1).

POTS = postural orthostatic tachycardia syndrome.

followed. Telemetry showed HR of 70 to 160 beats/min. Echocardiography was normal. Serology tests for severe acute respiratory syndrome-coronavirus-2 (SARS-CoV-2) were considered borderline. By

FIGURE 1 POTS Symptom Scoring in 42-Year-Old Woman

Patient 1 self-reported symptoms using a dedicated postural orthostatic tachycardia syndrome (POTS) symptom scoring questionnaire composed of 12 most commonly reported symptoms in POTS. Patients were asked to grade their symptoms using a visual analogue scale (VAS) ranging from 0 (no symptom) to 10 (worst possible). The maximum score is 120 points. A score >40 points likely indicates pathology.

FIGURE 2 HUT Testing in 42-Year-Old Woman

Head-up tilt (HUT) test revealing post-coronavirus disease 2019 POTS in a 42-year-old woman (Patient #1), with **red arrows** indicating the marked increase in heart rate (HR) during orthostasis. bpm = beats/min; Diz = dizziness; POTS = postural orthostatic tachycardia syndrome.

September, she was found unable to stand more than 5 min. Additionally, she complained of palpitations, dizziness, heat, and exercise intolerance (**Figure 1**). During a head-up tilt test, her HR increased from 85 beats/min supine to 135 beats/min upright within 10 min (**Figure 2**). Active standing showed initial orthostatic hypotension (**Figure 3**), whereas Valsalva maneuver showed a hyperadrenergic response characteristic for POTS (**Figure 4**).

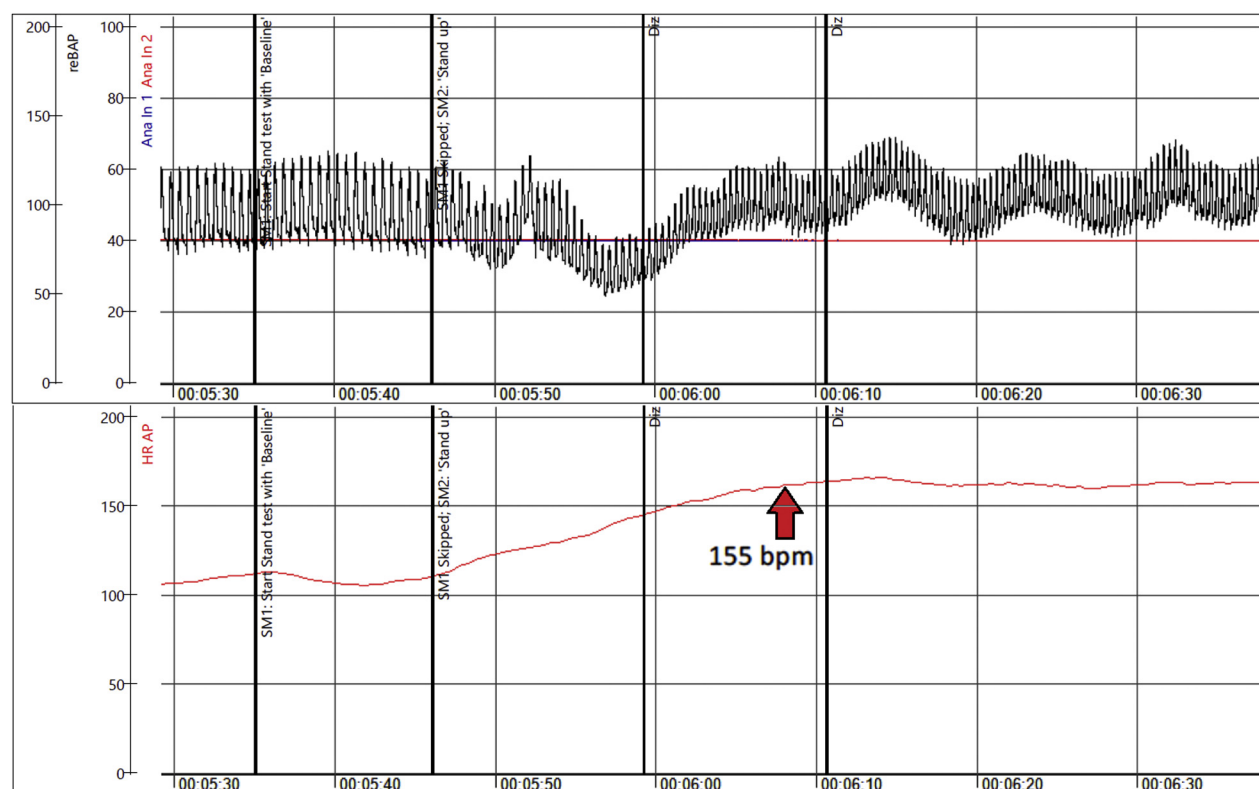
Ambulatory monitoring demonstrated a mean HR of 89 beats/min with episodic sinus tachycardia, maximum rate of 153 beats/min, while standing. Spirometry and cardiac magnetic resonance were normal. Autoimmunological screening of anti-phospholipid antibodies, antinuclear antibodies, antineutrophil cytoplasmic antibody was normal. Twenty-four-hour blood pressure (BP) monitoring showed average BP of 112/74 mm Hg, preserved

circadian profile, and lowest BP during daytime of 79/46 mm Hg.

Nonpharmacological measures including increased fluid intake, compression stockings, and avoidance of orthostatic triggers were recommended. She did not tolerate beta-blockers due to worsened orthostatic intolerance, and ivabradine 7.5 mg twice a day was started (**Table 2**) with substantial improvement, although the patient remains on sick leave.

PATIENT #2

A 28-year-old woman developed COVID-19 symptoms in May 2020 with fever, dyspnea, chest pain, light-headedness, and headache. Polymerase chain reaction testing was positive for SARS-CoV-2. Previous medical history included arthroscopic meniscectomy, tonsillectomy, and discectomy.

FIGURE 3 Active Standing in 42-Year-Old Woman

Active standing test demonstrating initial orthostatic hypotension and POTS in a 42-year-old woman (Patient #1) with long-haul post-coronavirus disease-2019 symptoms, with **red arrow** indicating the marked increase in heart rate during orthostasis. Abbreviations as in [Figures 1 and 2](#).

Due to persistent and progressive symptoms (chest pain, fatigue, vertigo, headache), she was hospitalized twice. Blood tests were normal except slight leukocytosis. Chest computed tomography excluded pulmonary embolism and viral pneumonia but revealed pericardial effusion. As pericarditis was suspected, prednisolone was started, and subsequently changed to colchicine and ibuprofen, with no effect on symptoms. Due to headache, nausea, and photophobia, viral meningitis was suspected. However, lumbar puncture and spine and brain magnetic resonance imaging scan were normal.

An active standing test demonstrated HR increase from 75 to 128 beats/min with concomitant slight increase in systolic BP (10 mm Hg) and pronounced orthostatic intolerance (dizziness, lightheadedness, tremor) ([Figure 5](#)).

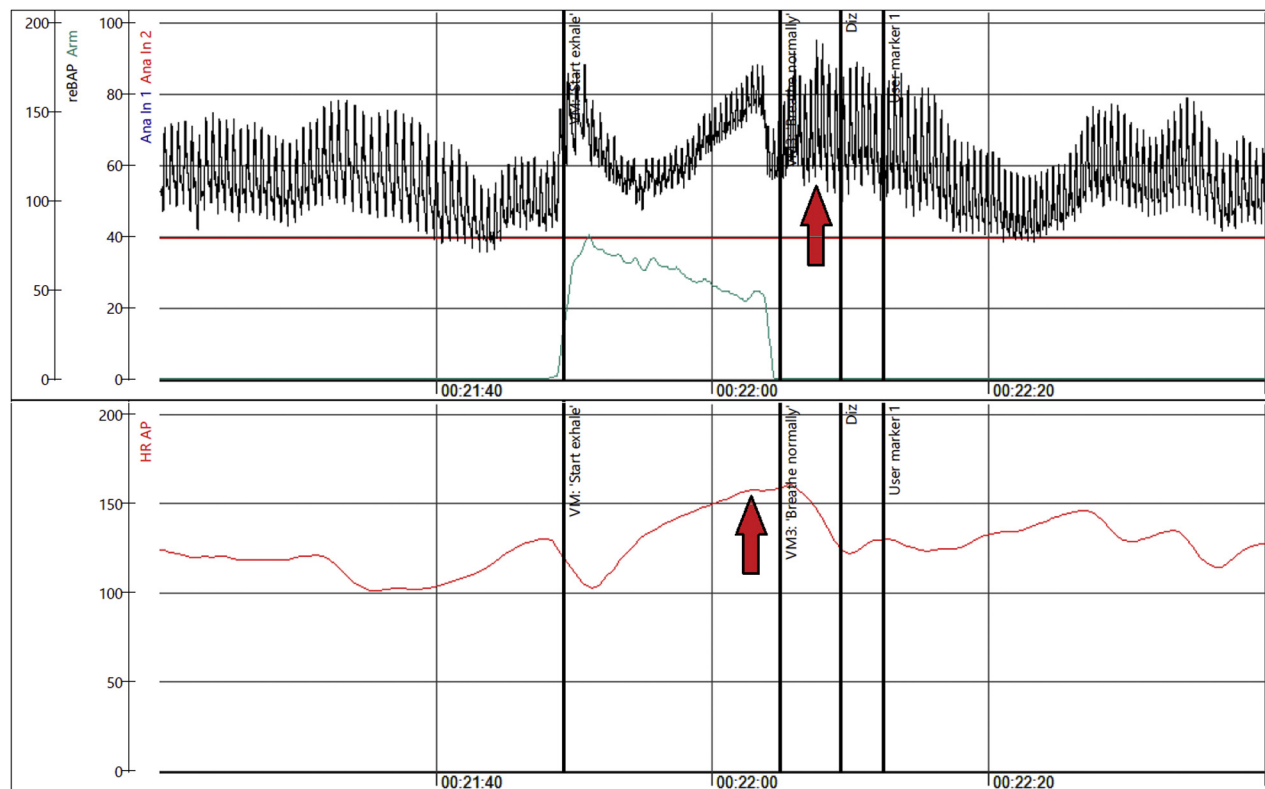
In September, she was referred to a tertiary center for post-COVID-19 follow-up and tested positive for SARS-CoV-2 immunoglobulin G antibodies. During a 6-min walking test peripheral oxygen desaturation was noted (from 99% to 89%) without any other findings.

Further evaluation with perfusion stress cardiac magnetic resonance, antinuclear antibodies, antineutrophil cytoplasmic antibody, metoxycatecholamines, and antiphospholipid autoantibodies was normal. POTS was confirmed by both active standing test and head-up tilt (symptomatic sinus tachycardia >130 beats/min).

Non-pharmacological recommendations included increased daily fluid and salt intake, as well as use of compression socks. She was prescribed propranolol 10 mg \times 3 times a day ([Table 2](#)). After several weeks, she developed gastrointestinal symptoms, itching, and orbital edema. Because concomitant mast cell activation syndrome was suspected, she received H1 and H2 antihistamines but remains highly symptomatic and is on sick leave.

PATIENT #3

In May 2020, a 37-year-old man developed sore throat, fever, fatigue, muscle weakness, dry cough, and palpitations. He had a history of childhood sepsis

FIGURE 4 Valsalva Response in 42-Year-Old Woman

Hyperadrenergic Valsalva maneuver in a 42-year-old woman (Patient #1) with long-haul post-coronavirus disease 2019 symptoms, with red arrows indicating the marked increase in heart rate and blood pressure (hyperadrenergic response). Abbreviations as in Figure 2.

and migraine. Polymerase chain reaction testing for SARS-CoV-2 and antibodies was negative on multiple occasions. Although not initially hospitalized, the patient was later admitted twice during the summer due to severe and persistent symptoms of extreme fatigue, muscle weakness, insomnia, palpitations, and “brain fog” with trouble concentrating.

A chest computed tomography revealed no signs of viral pneumonia. Myositis and neurological complications were initially suspected; however, the full-body magnetic resonance imaging (including brain and neck) was normal. Lumbar puncture, echocardiography, and laboratory work-up were normal. Skeletal muscle biopsy revealed minimal enrichment of inflammatory cells with unclear significance. Marked fluctuations in sinus rate (periodic increases >140 beats/min with minimal effort) were noted on telemetry. An active standing test demonstrated increase in sinus rate from 98 to 142 beats/min, whereas BP remained stable. POTS was confirmed.

He was referred to a tertiary center for post-COVID-19 follow-up. Additional tests were negative for anti-nuclear antibodies, antineutrophil cytoplasmic antibody, and metoxycatecholamines. Anticardiolipin and anti-beta-2-glycoprotein-2 immunoglobulin M were slightly elevated (9 E/ml, with values >30 diagnostic for antiphospholipid syndrome).

Recommendations were given to increase fluid and salt intake and use compression socks (Table 2). The patient received propranolol 10 mg ×3 times a day and pyridostigmine 10 mg ×3, the latter due to severe fatigue and muscle weakness. In addition to typical POTS symptoms he developed nausea, orbital edema, and gastrointestinal symptoms (Figure 6). Empirical treatment with H1 and H2 antihistamines was initiated due to suspected mast cell activation syndrome, with moderate clinical improvement. Despite up-titration of propranolol and pyridostigmine, he is still highly symptomatic and on sick leave.

TABLE 2 Proposed Treatment of POTS

Drugs	Dosage	Side Effects	Precautions
Nonpharmacological Treatments			
Withdraw exacerbating medications	Stop drugs that decrease blood volume or directly increase heart rate		
Increased oral water intake	Target 2-3 l/day	Frequent urination	
Increased oral NaCl intake	Target 8-10 g/day	Hypertension, peripheral edema	Buffered NaCl tablets can be used if this cannot be done with diet alone
Lower body compression garments	20-40 mm Hg compression; focus on abdomen ± legs	Can be hot, tight, and itchy	
Exercise training	Aerobic: 30+ min 4 days/week with some leg resistance training	Will initially feel poorly and/or worse for up to 6 weeks	Initial recumbent exercise, such as a rowing machine, recumbent cycle, or swimming are preferred
Pharmacological Treatments			
Blood volume expanders			
Fludrocortisone	0.1-0.2 mg daily	Hypokalemia, edema, headache	Electrolytes should be monitored
Desmopressin (DDAVP)	0.1-0.2 mg as needed	Hyponatremia, edema	Electrolytes should be monitored if used chronically
Acute IV saline	2 l IV over 2-3 h	Venous thrombosis, infection	
Chronic IV saline	2 l given IV once weekly	Infection risk of central venous catheters	Avoid long-term use and placement of central catheters
Erythropoietin	10,000 IU weekly	Increased risk of cardiovascular death	Hematocrit should be monitored
Heart rate inhibitors			
Propranolol	10-20 mg orally up to 4× daily	Hypotension, bradycardia, bronchospasm	Can worsen asthma or exercise tolerance
Ivabradine	2.5-7.5mg orally twice daily	Headaches, palpitations, hypertension, visual disturbances	
Pyridostigmine	30-60 mg orally up to 3× daily	Abdominal cramps, diarrhea	Can worsen asthma
Vasoconstrictors			
Midodrine	2.5-15 mg orally 3× daily	Headache, scalp tingling, hypertension	
Octreotide	Long-acting intramuscular injection 10-30 mg	Nausea, stomach cramps, diarrhea	
Methylphenidate	10 mg orally 2× to 3× a day. Last dose should be avoided before bed	Tachycardia, insomnia, nausea, headache, dizziness	
Droxidopa	100-600 mg 3× daily	Headache, nausea, hypertension, and tachycardia	Off-label use only
Sympatholytic drugs			
Alpha2 adrenergic agonists, such as clonidine	0.1-0.2 mg orally 2× to 3× daily or long-acting patch	Hypotension, fatigue, brain fog	
Methyldopa	125-250 mg orally twice daily	Hypotension, fatigue, brain fog	
Other			
Modafinil	50-200 mg orally once or twice daily	Tachycardia	

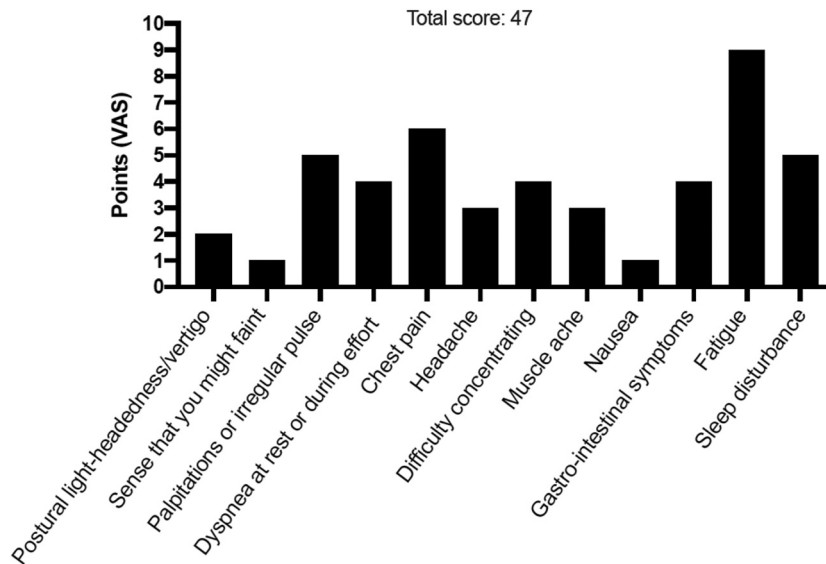
Adapted with permission from Miller and Raj (9).

DDAVP = Desmopressin; IU = international units; IV = intravenous(ly); POTS = postural orthostatic tachycardia syndrome.

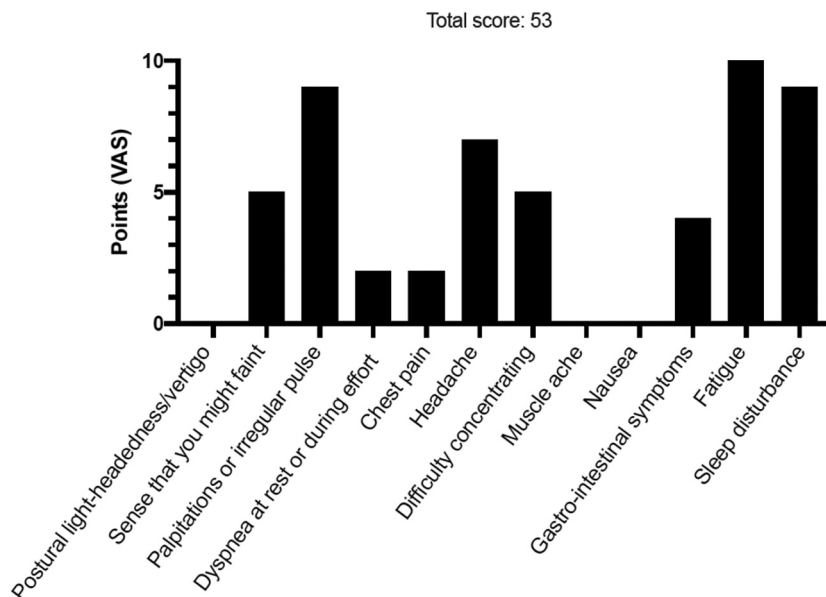
DISCUSSION

We describe 3 Swedish patients diagnosed with POTS-like symptoms following probable COVID-19 infections. Patients were diagnosed on the grounds of characteristic orthostatic tachycardia and chronic symptoms of orthostatic intolerance after exclusion of competing etiologies (Table 1).

POTS affects primarily women (≈80%) and is manifested by orthostatic tachycardia, in association with various symptoms including palpitations, dizziness, headache, fatigue, and blurred vision (1,2) (Table 3). The syndrome can be precipitated by viral illness or severe infection (5) in 30% to 50% of all patients. The mechanism of POTS is generally undetermined. Similarly, the mechanism of post-COVID-19

FIGURE 5 POTS Symptom Scoring in 28-Year-Old Woman

Patient #2 self-reported symptoms using a dedicated POTS symptom scoring questionnaire composed of 12 most commonly reported symptoms in POTS. Patients were asked to grade their symptoms using a VAS ranging from 0 (no symptom) to 10 (worst possible). The maximum score is 120 points. A score >40 points likely indicates pathology. Abbreviations as in [Figure 1](#).

FIGURE 6 POTS Symptom Scoring in 37-Year-Old Man

Patient #3 self-reported symptoms using a dedicated POTS symptom scoring questionnaire composed of 12 most commonly reported symptoms in POTS. Patients were asked to grade their symptoms using a VAS ranging from 0 (no symptom) to 10 (worst possible). The maximum score is 120 points. A score >40 points likely indicates pathology. Abbreviations as in [Figure 1](#).

TABLE 3 Typical Clinical Presentation of POTS

Cardiovascular Symptoms (Pathognomonic)	
Cardiovascular system	Main: orthostatic intolerance, orthostatic tachycardia, palpitations, dizziness, lightheadedness, (pre-)syncope, exercise intolerance Other frequent symptoms: dyspnea, chest pain/discomfort, acrocyanosis, Raynaud phenomenon, venous pooling, limb edema
Noncardiovascular Symptoms (Accompanying)	
General symptoms	General deconditioning, chronic fatigue, exhaustion, heat intolerance, fever, debility, bedridden
Nervous system	Headache/migraine, mental clouding ("brain fog"), cognitive impairment, concentration problems, anxiety, tremulousness, light and sound sensitivity, blurred/tunnel vision, neuropathic pain (regional), sleeping disorders, involuntary movements
Musculoskeletal system	Muscle fatigue, weakness, muscle pain
Gastrointestinal system	Nausea, dysmotility, gastroparesis, constipation, diarrhea, abdominal pain, weight loss
Respiratory system	Hyperventilation, bronchial asthma, shortness of breath
Urogenital system	Bladder dysfunction, nocturia, polyuria
Skin	Petechiae, rashes, erythema, telangiectasias, abnormal sudomotor regulation, diaphoresis, pallor, flushing

Adapted with permission from Fedorowski (1).
POTS = postural orthostatic tachycardia syndrome.

POTS remains unknown, although a chronic inflammatory or autoimmune response may be at play. Whereas few reports have been published (6,7), the number of patients affected by long-haul post-COVID-19 will likely grow.

Negative SARS-CoV-2 test results do not exclude SARS-CoV-2 infection and ought to be interpreted with caution in the context of typical symptoms (8). In the differential diagnosis of POTS, it is important to consider and exclude other identifiable causes of sinus tachycardia such as dehydration, other infections, hyperthyroidism, cardiac disease, anxiety, anemia, metabolic disorders, chronic fatigue syndrome, or deconditioning (5) (Table 1).

Available management protocols for POTS (Table 2) aim at increasing intake of fluids (water) and salt, physical countermeasures, and individually adapted aerobic exercise in recumbent position (1,5,9) to help correct the physiological abnormalities.

Pharmacotherapy includes volume expanders, vasoconstrictors, and HR regulators but patients may remain symptomatic and incapable of work.

Much remains unknown about the specific mechanisms responsible for the POTS-like symptoms in post-COVID-19 patients or how long these symptoms will last but chronic symptoms are expected in a subset of patients based on this initial clinical experience.

FUNDING SUPPORT AND AUTHOR DISCLOSURES

The authors have reported that they have no relationships relevant to the contents of this paper to disclose.

ADDRESS FOR CORRESPONDENCE: Dr. Madeleine Johansson, Department of Clinical Sciences, Lund University, Clinical Research Center, Box 50332, 20213, Malmö 20213, Sweden. E-mail: madeleine.johansson@med.lu.se. Twitter: [@DrMJohansson](https://twitter.com/DrMJohansson), [@ArturFedorowski](https://twitter.com/ArturFedorowski).

REFERENCES

- Fedorowski A. Postural orthostatic tachycardia syndrome: clinical presentation, aetiology and management. *J Intern Med* 2019;285:352–66.
- Bryarly M, Phillips LT, Fu Q, Vernino S, Levine BD. Postural orthostatic tachycardia syndrome: JACC focus seminar. *J Am Coll Cardiol* 2019;73:1207–28.
- Vernino S, Stiles LE. Autoimmunity in postural orthostatic tachycardia syndrome: current understanding. *Auton Neurosci* 2018;215:78–82.
- Wiersinga WJ, Rhodes A, Cheng AC, Peacock SJ, Prescott HC. Pathophysiology, transmission, diagnosis, and treatment of coronavirus disease 2019 (COVID-19): a review. *JAMA* 2020;324:782–93.
- Olshansky B, Cannon D, Fedorowski A, et al. Postural orthostatic tachycardia syndrome (POTS): a critical assessment. *Prog Cardiovasc Dis* 2020;63:263–70.
- Miglis MG, Prieto T, Shaik R, Muppidi S, Sinn DI, Jaradeh S. A case report of postural tachycardia syndrome after COVID-19. *Clin Auton Res* 2020;30:449–51.
- Kanjwal K, Jamal S, Kichloo A, Grubb BP. New-onset postural orthostatic tachycardia syndrome following coronavirus disease 2019 infection. *J Innov Card Rhythm Manag* 2020;11:4302–4.
- Watson J, Richter A, Deeks J. Testing for SARS-CoV-2 antibodies. *BMJ* 2020;370:m3325.
- Miller AJ, Raj SR. Pharmacotherapy for postural tachycardia syndrome. *Auton Neurosci* 2018;215:28–36.

KEY WORDS autonomic dysfunction, complications, COVID-19 infection, orthostatic intolerance, postural orthostatic tachycardia syndrome